

## BRIEF ARTICLE

## Perioral Contact Dermatitis Caused by Limonene Hydroperoxide in Cannabis Vaping Products

Kevin Mai<sup>1</sup>, Quang D. Pham<sup>1</sup>, Joseph Haquang<sup>1</sup>, Diem Q. Pham, DO<sup>1,2</sup>

<sup>1</sup> College of Osteopathic Medicine of the Pacific, Western University of Health Sciences, Pomona, California

<sup>2</sup> Sand Dermatology, Chino Hills, CA

### ABSTRACT

Limonene is a fragrant terpene commonly found in household and cosmetic products due to its fresh aroma. When exposed to air, limonene autoxidizes to form limonene hydroperoxide, a potent allergen that can cause allergic contact dermatitis. Recently, as the popularity and availability of limonene increased, it has been incorporated into novel products such as flavoring agents for electronic cigarettes or vapes. With the rising acceptance and popularity of marijuana, this usage has extended to cannabis vaping products. Here, we report an unusual presentation of an allergic contact dermatitis reaction to limonene hydroperoxide stemming from cannabis vaping products.

### INTRODUCTION

Limonene is a fragrant hydrocarbon monoterpene compound naturally found in plants, spices, and citrus oils.<sup>1</sup> Due to its desirable aromatic qualities, it is one of the most common chemical additives in household products including cosmetics, essential oils, and cleaning supplies.<sup>1</sup> The non-oxidized form of limonene can cause a weak fragrance allergy.<sup>2</sup> When exposed to air, however, limonene rapidly autoxidizes and generates limonene hydroperoxide, a more potent contact sensitizer that has been noted to cause allergic contact dermatitis (ACD).<sup>2,3</sup>

Limonene's availability and popularity has extended its use to novel products that use aerosolization such as electronic cigarettes or vapes.<sup>4</sup> Specifically, limonene is used as a flavoring agent within vaping liquid. The

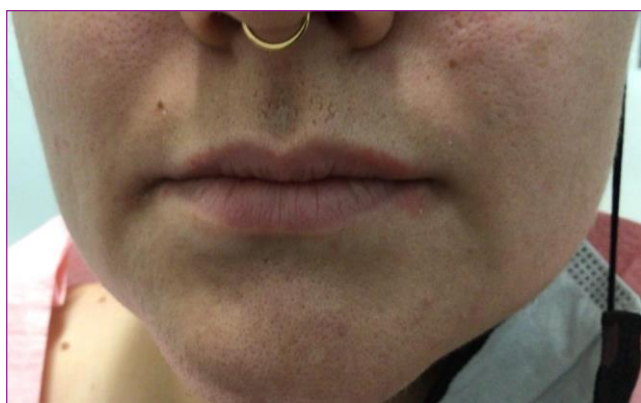incorporation of limonene into these devices may lead to new presentations of limonene hydroperoxide allergic contact dermatitis. Previous literature describes how limonene can cause a strong hypersensitivity reaction in individuals and may be more prevalent in those who work with limonene containing cosmetics. The description of how this may specifically present has been extremely limited.<sup>5</sup> Here, we report a case of an allergic contact dermatitis reaction to limonene hydroperoxide from cannabis vaping products presenting as a perioral rash. To the best of our knowledge, a case of contact dermatitis arising from limonene hydroperoxide found in cannabis vaping products has yet to be reported.

### CASE REPORT

A 31-year-old female presents for a worsening pruritic perioral rash that has been

March 2023 Volume 7 Issue 2

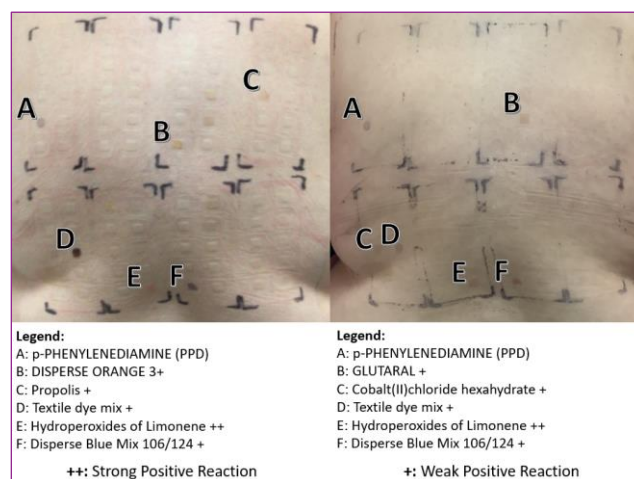
present for one and a half years. She reports a significant history of acne, chronic back pain, scoliosis and an allergy to morphine. Her medications include buspirone, cannabidiol, gabapentin, propranolol, prozac, trazodone, xanax and omeprazole. Physical examination demonstrated angular cheilitis and dry lips at the periphery with fissures and erythema involving the bilateral superior cutaneous lip and apical triangles (**Figure 1**). A serum vitamin, nicotinamide and zinc panel were ordered to rule out any vitamin deficiencies. Zinc, nicotinamide and vitamin B1, B2, B3, B9 and B12 levels were unremarkable. A trial of topical 2% ketoconazole cream and topical 0.05% desonide ointment were ordered.



**Figure 1.** Angular cheilitis and dry lips at the periphery with fissures and erythema involving the bilateral superior cutaneous lip and apical triangles.

Three months later, the patient returns with continual recurrence of her perioral rash. A patch test was conducted using the North American 80 comprehensive series. Results from the first reaction were strongly positive for hydroperoxides of limonene and weakly positive for propolis, textile dye mix, disperse blue mix 106/124 and disperse orange 3 (**Figure 2, Left**). Results from the second reaction were strongly positive for disperse blue mix 106/124 and weakly positive for limonene hydroperoxides, textile dye mix, glutaral, cobalt (II) chloride hexahydrate and

p-phenylenediamine (**Figure 2, Right**). Upon further questioning she mentions that she has been consuming marijuana every two to three days for her chronic back pain through a vaping device. The patient was then prescribed a three-week course of fluconazole and a four-week trial of alclomethasone cream and informed to utilize a barrier for her lips when using the vape or to avoid using her marijuana vape altogether. A consequent follow-up showed continuation of the symptoms as the patient mentioned she was unable to taper down her use of the cannabis vape and that it continued to contact her lips. A crisaborole ointment was ordered instead for an expected long-term usage. Crisaborole proved to be effective in controlling the perioral rash from June 2022 to December 2022. Afterwards, our patient reported it was no longer effective. The patient was instructed to return for a follow up visit for a trial of ruxolitinib cream thereafter. As of now, the patient has not yet scheduled a follow up appointment.



**Figure 2.** Patch testing with the North American 80 comprehensive series.

## DISCUSSION

ACD is an inflammatory disorder of the skin resulting from an immune-mediated delayed hypersensitivity reaction.<sup>6</sup> The nature of this

condition is dependent on the sensitization of T- cells following initial contacts with an allergen.<sup>6</sup> The prevalence of ACD is rising globally with an estimated 20% of the general population affected.<sup>7</sup> Patch testing has demonstrated that the frequency of limonene hydroperoxide sensitization ranges from an estimated 2.5% to 9.4%.<sup>8</sup> This frequency is expected to increase with the coming years possibly due to the increasing popularity and availability of limonene.

The clinical presentation of the patient's angular cheilitis like rash and dry lips are nonspecific findings, overlapping with many other common pathologies such as candida perleche or vitamin deficiencies.<sup>9</sup> Hence, an unremarkable serum vitamin panel and persistence of the rash despite topical and oral antifungals helped rule out these differential diagnoses. Additionally, her history of cannabis vaping, a positive patch testing for limonene and no other contributory factors, makes limonene hydroperoxide ACD the likely culprit behind the lesions. The similarity in presentation between various diseases can hinder the diagnosis, delay removal of allergen exposure, and treatment of limonene triggered ACD. Therefore, to aid in differentiation between limonene triggered ACD versus other pathologies, we highlight a unique location of the rash. Specifically, our patient's rash had a distinct predominance to the superior aspect of the lip and the apical triangles rather than simply adjacent to the mouth. Because the rash stems from cannabis vaping, its location is likely caused by inhalation and expulsion of aerosolized limonene through the nostrils.<sup>3</sup> Overall, awareness of this possible presentation, obtaining a detailed history of allergen exposure, and examining the rash's location can aid in diagnosing limonene hydroperoxide ACD from cannabis vaping products.

Due to varied allergen exposure based on a patient's unique environment, ACD's presentation and epidemiology can differ between patients and geographic locations.<sup>10</sup> Differences in environmental allergen exposure may be explained by cultural or policy changes such as marijuana's legalization in several US states and worldwide. Globally, the incidence of e-cig usage is rising. This phenomenon is likely due to the increasing legalization, social acceptance, and usage of recreational marijuana and electronic cigarettes in youths. Many teenagers and adults are also drawn to electronic vapes due to the novelty and allure of trying different flavored solutions, causing increased exposure to limonene.<sup>11</sup>

## CONCLUSION

In summary, we have presented an uncommon and previously unreported case of limonene hydroperoxide-associated ACD from cannabis vaping. Improved patient education involving both the adverse respiratory effects of e-cigarettes and cutaneous reactions could be instrumental in reducing limonene hydroperoxide-triggered ACD.

**Conflict of Interest Disclosures:** None

**Funding:** None

**Corresponding Author:**

Kevin Mai  
College of Osteopathic Medicine of the Pacific  
Western University of Health Sciences  
309 E 2<sup>nd</sup> St.  
Pomona, CA 91766  
Email: kevin.mai@westernu.edu

**References:**

1. Anandakumar P, Kamaraj S, Vanitha MK. D-limonene: A multifunctional compound with potent therapeutic effects. *J Food Biochem*. Jan 2021;45(1):e13566. doi:10.1111/jfbc.13566

March 2023 Volume 7 Issue 2

2. Christensson JB, Johansson S, Hagvall L, Jonsson C, Borje A, Karlberg AT. Limonene hydroperoxide analogues differ in allergenic activity. *Contact Dermatitis*. Dec 2008;59(6):344-52. doi:10.1111/j.1600-0536.2008.01442.x
3. de Groot A. Limonene Hydroperoxides. *Dermatitis*. Nov/Dec 2019;30(6):331-335. doi:10.1097/DER.0000000000000465
4. Bitzer ZT, Goel R, Reilly SM, et al. Effect of flavoring chemicals on free radical formation in electronic cigarette aerosols. *Free Radic Biol Med*. May 20 2018;120:72-79. doi:10.1016/j.freeradbiomed.2018.03.020
5. Pesonen M, Suomela S, Kuuliala O, Henriks-Eckerman ML, Aalto-Korte K. Occupational contact dermatitis caused by D-limonene. *Contact Dermatitis*. Nov 2014;71(5):273-9. doi:10.1111/cod.12287
6. Mowad CM, Anderson B, Scheinman P, Pootongkam S, Nedorost S, Brod B. Allergic contact dermatitis: Patient diagnosis and evaluation. *J Am Acad Dermatol*. Jun 2016;74(6):1029-40. doi:10.1016/j.jaad.2015.02.1139
7. Peiser M, Tralau T, Heidler J, et al. Allergic contact dermatitis: epidemiology, molecular mechanisms, in vitro methods and regulatory aspects. Current knowledge assembled at an international workshop at BfR, Germany. *Cell Mol Life Sci*. Mar 2012;69(5):763-81. doi:10.1007/s00018-011-0846-8
8. Dittmar D, Schuttelaar MLA. Contact sensitization to hydroperoxides of limonene and linalool: Results of consecutive patch testing and clinical relevance. *Contact Dermatitis*. Feb 2019;80(2):101-109. doi:10.1111/cod.13137
9. Federico JR, Basehore BM, Zito PM. Angular Chelitis. *StatPearls*. 2022.
10. Cappelli L, Poiset S, Greenberger B, Bar-Ad V. Thermoplastic Mask-Induced Contact Dermatitis: A Case Report. *Cureus*. Apr 2022;14(4):e23815. doi:10.7759/cureus.23815
11. Jones K, Salzman GA. The Vaping Epidemic in Adolescents. *Mo Med*. Jan-Feb 2020;117(1):56-58.