

BRIEF ARTICLE

Dupilumab-induced Acanthosis Nigricans

Marita Yaghi, MD^{1*}, Teresa Ju, MD^{1*}, Jamie Katy Hu, MD¹, Arvin Jadoo, MD¹, Andrea Maderal, MD¹

¹ Dr. Phillip Frost Department of Dermatology and Cutaneous Surgery, University of Miami, Miller School of Medicine, Miami, FL

ABSTRACT

Dupilumab is a human monoclonal IgG4 antibody to interleukin-4 (IL-4) and IL-13 approved for the treatment of moderate-to-severe atopic dermatitis (AD) in patients six months or older. Several cutaneous adverse reactions to dupilumab have been reported, including facial dermatitis and psoriasis. Herein, we present a unique case of dupilumab-induced acanthosis nigricans (AN) in a patient treated for concomitant AD and contact dermatitis, in the absence of other associated conditions or potential culprit medications. The patient had complete resolution of the lesions with discontinuation of medication, and recurrence upon re-initiation of therapy. This case represents a new cutaneous adverse reaction to dupilumab to which dermatologists should be familiar.

INTRODUCTION

Dupilumab is a human monoclonal IgG4 antibody to the interleukin-4R α (IL-4R α) subunit shared by both the IL-4 and IL-13 receptor complexes. IL-4R α can be found on many cell types (mast cells, eosinophils, macrophages, lymphocytes, epithelial cells, goblet cells) involved in inflammation. Dupilumab blocking of IL-4R α inhibits IL-4 and IL-13 signaling and, therefore, their inflammatory release of cytokines, chemokines, nitric oxide, and IgE. It has been approved for the treatment of moderate-to-severe atopic dermatitis (AD) in patients six months or older and asthma in patients 12 years or older. Additionally, dupilumab is also utilized in adults with chronic rhinosinusitis with nasal polyposis.^{1,2} Common adverse reactions include local injection-site reactions, upper respiratory tract infections, antibody development, ocular surface

disorders, and a wide array of dermatologic reactions. To our knowledge, there have been no reports of drug-induced acanthosis nigricans (AN) in association with dupilumab. Herein, we present a unique case of dupilumab-induced acanthosis nigricans (AN) in a patient treated for concomitant AD and contact dermatitis.

CASE REPORT

A 48-year-old Hispanic female with a history of hypothyroidism and iron deficiency anemia presented to the clinic with a 5-year history of recalcitrant biopsy-proven atopic dermatitis. She had failed numerous medications, and finally was started on subcutaneous dupilumab, beginning with a loading dose of 600 mg, and followed by 300 mg every two weeks with substantial clinical improvement. However, approximately one month after initiation of dupilumab, the patient noticed

March 2024 Volume 8 Issue 2

darkening of the bilateral axillae and groin area. The rash progressed over several months without associated itching, burning or pain. Following 18 months of therapy, the patient discontinued injections due to loss of insurance coverage and upon discontinuation of the medication, the hyperpigmented plaques began to fade, with complete resolution over two months.

The patient's atopic dermatitis began to flare off therapy, and therefore, she was restarted on the same maintenance regimen of dupilumab 300 mg every two weeks leading to improvement of her dermatitis, but again, she developed asymptomatic darkening of the bilateral axilla and inguinal folds and returned for evaluation. The patient denied any recent weight change, new medications, or abnormal findings on age-appropriate malignancy screenings such as mammography and pap smear. On physical examination, the patient had velvety, hyperpigmented, corrugated plaques in the bilateral axillae and inguinal folds (**Figure 1**), consistent with AN. Given concern for potential metabolic derangements associated with AN, a metabolic panel was attained, revealing TSH, fasting glucose, glycosylated hemoglobin levels and insulin analyte levels within the normal range. The patient denied a skin biopsy, and a clinical diagnosis of drug-induced acanthosis nigricans due to dupilumab was rendered.

At 6-month follow-up after re-initiation of dupilumab, the patient achieved good control of her dermatitis, but the acanthosis nigricans-like plaques persisted without any associated symptoms. She remains on the same dupilumab regimen.

DISCUSSION

Since its approval for use by the Food and Drug Administration (FDA) in 2017, dupilumab has proven to be a highly effective and safe medication for multiple pathologies such as atopic dermatitis. Excellent outcomes have been reported in up to 69% of patients with moderate to severe atopic dermatitis, showing an improvement of at least 75% as by the Eczema Area and Severity Index (EASI), with 59% reporting \geq 4-points improvement in their pruritus as delineated by the Numeric Rating Scale (NRS).³ Numerous large-scale trials and case reports have described a wide range of dermatologic adverse effects secondary to dupilumab, summarized in **Table 1**. Still, none of these emerging studies have described a case similar to our patient's.

Drug-induced AN is an uncommon subtype of AN and can be caused by a variety of drugs, both topical and systemic. The most commonly implicated include nicotinic acid, insulin, oral corticosteroid, and diethylstilbestrol, and the eruption typically develops in a gradual fashion months after drug initiation.⁴ Drug-induced AN is often thought to occur due to metabolic changes caused by the drugs implicated, which may lead to hyperinsulinemia and activation of insulin-like growth factor (IGF-1), which stimulate epithelial keratinocyte proliferation.^{4,5} There have also been several case reports that suggest that dupilumab may cause metabolic changes in rare cases. Dupilumab-associated acute pancreatitis has been reported in two otherwise healthy adolescent males,⁶ and dupilumab has also been reported to be associated with the development of type I diabetes.⁷

Our patient presented with asymptomatic darkening of intertriginous areas that are classically associated with AN. The self-resolving nature of her rash upon discontinuation of dupilumab, lack of other

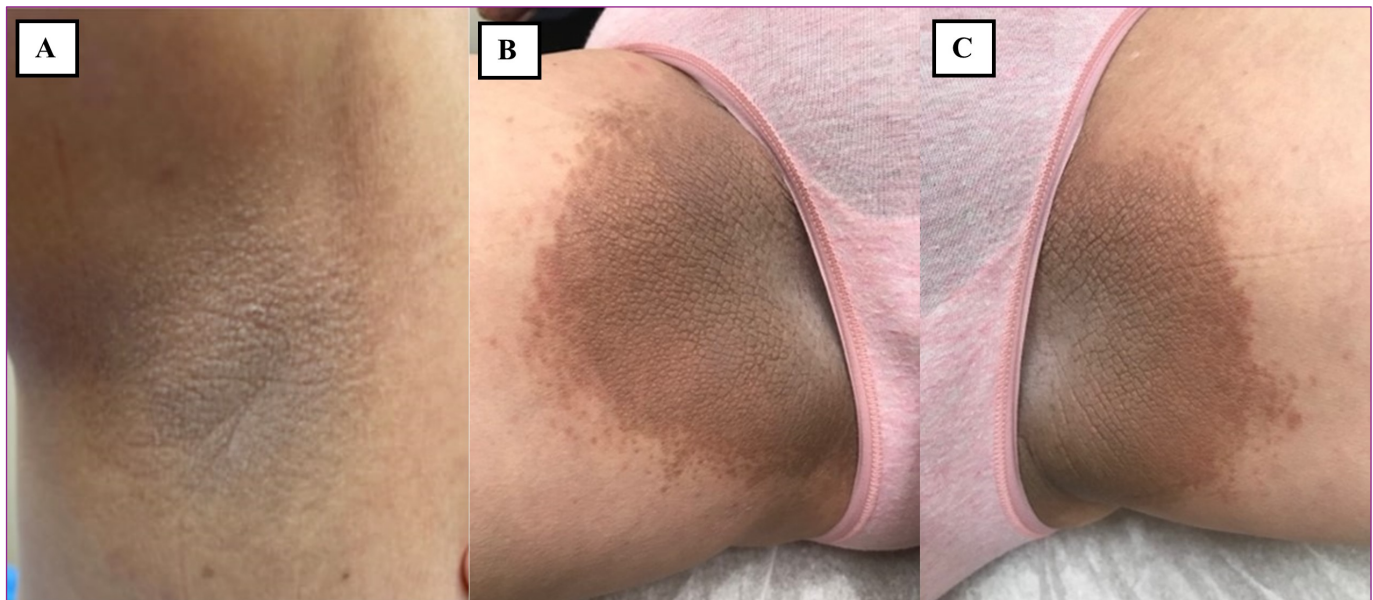


Figure 1. Velvety hyperpigmented corrugated plaques in the a. Right axilla b. Right inguinal fold c. Left inguinal fold

Table 1. A summary of reported dermatologic adverse effects with the use of dupilumab

	Indication	Dosage	Cutaneous reaction reported	Duration of dupilumab therapy before AE	Treatment/ outcomes	Dupilumab discontinuation	Proposed mechanism
Sumi T. et al.	Asthma	Not reported	Delayed injection site reaction	Day 3 on site 1 Day 12 on Site 2	Spontaneous resolution	No	Subcutaneous residual polysorbate metabolites deposition (formulation excipient)
Wenzel S. et al.	Asthma	300 mg q1w	Progressive papular rash (distant to injection site)	By week 12	Prednisone + diphenhydramine + resolution	No	Not reported
			Urticaria	By week 12	Prednisone + diphenhydramine + resolution	No	Not reported
Thaçi D. et al	Atopic dermatitis	600 mg loading dose then 300 mg q1week	Non-herpetic skin infections	Not reported	Not reported	Not reported	Not reported
			Skin structures and soft tissue infections				
			Herpes simplex				
			Eczema herpeticum				
			Herpes zoster				
			Genital herpes				
			Exacerbation of atopic dermatitis				
			Injection-site reactions				

SKIN

Ahatov R. et al.	Atopic dermatitis	Not reported	Primary cutaneous $\gamma\delta$ T-cell lymphoma	1 year	Patient death	NA	Possible immunomodulatory shift
Poyner et al.	Atopic dermatitis	Not reported	Unmasking of cutaneous T-cell lymphoma	9 weeks	Patient death	NA	Not reported
Phan M. et al.	Atopic dermatitis	600 mg loading dose then 300 mg q2weeks	Ulcerative injection site reaction	6 weeks	Hydrocolloid dressings + petrolatum for 2 m + resolution	No	Repeat ulcerative reaction with perilesional soft tissue swelling
Fritz et al.	Atopic dermatitis	Not reported	Angioedema (note: pediatric patient)	4 weeks	Medication discontinuation + resolution	Yes	Sensitization in allergic angioedema
Mustin et al.	Atopic dermatitis	600 mg loading dose then 300 mg q2weeks	Erythema nodosum	8 weeks	Medication discontinuation + switching to Omalizumab	Yes	Not reported
Barbarin et al.	Atopic dermatitis	600 mg loading dose	Alopecia areata	48 h	Medication discontinuation + resolution	Yes	Not reported
DeGrazia et al.	Atopic dermatitis	Not reported	Scalp psoriasis (3 patients)	1 month, 2 months, 9 months	Not reported	Not reported	Not reported
Napolitano et al.	Atopic dermatitis	600 mg induction dose and then 300 mg every 2 weeks	Psoriasis	1 month, 5 months, and 6 months	1 patient: discontinuation 2 patients: topical steroids/systemic steroids achieved control	Yes (1/3)	Not reported
Jo et al.	Atopic dermatitis	Multiple regimens	Facial erythema	Various	16 patients included with different Rx	Yes (6/16)	Not reported
Muzumdar et al.	Atopic dermatitis	Not reported	Pediatric facial erythema 7/24	Various	Not reported	Not reported	Seborrheic dermatitis-like IL-4R blockade facilitating a T17-mediated hypersensitivity response

medications, as well as the absence of comorbid obesity, insulin resistance, or notable findings on age-appropriate malignancy screening support a diagnosis of AN induced by dupilumab. As dupilumab has led to development of other metabolic conditions affecting insulin signaling pathway, this may be the etiology of drug-induced AN, though insulin levels were normal in the patient.

This case highlights AN as an adverse effect of dupilumab, which to the authors' knowledge, is the first report. Given the benign nature of this adverse effect, and the lack of symptoms or distress experienced by our patient, treatment with dupilumab was not discontinued. However, as we observed spontaneous resolution of the AN upon medication discontinuation when the insurance did not provide coverage, patients experiencing this complication may have complete clearance upon discontinuation of the medication.

*Co-first authors

Conflict of Interest Disclosures: None

Funding: None

Corresponding Author:

Andrea Maderal, MD
 1600 NW 10th Ave RMSB 2023A, Miami, Florida
 Phone: 305-243-4472
 Email: AMaderal@med.miami.edu

References:

1. FDA. *DUPIXENT® (dupilumab) injection, for subcutaneous use.* 2017. https://www.accessdata.fda.gov/drugsatfda_docs/label/2017/761055lbl.pdf
2. FDA approves Dupixent® (dupilumab) as first biologic medicine for children aged 6 months to 5 years with moderate-to-severe atopic dermatitis. 2022. <https://www.sanofi.com/en/media-room/press-releases/2022/2022-06-07-20-45-00-2458243>

3. Blauvelt A, de Bruin-Weller M, Gooderham M, et al. Long-term management of moderate-to-severe atopic dermatitis with dupilumab and concomitant topical corticosteroids (LIBERTY AD CHRONOS): a 1-year, randomised, double-blinded, placebo-controlled, phase 3 trial. *The Lancet.* 2017;389(10086):2287-2303.
4. Mourad AI, Haber RM. Drug-induced acanthosis nigricans: A systematic review and new classification. *Dermatol Ther.* Mar 2021;34(2):e14794. doi:10.1111/dth.14794
5. Das A, Datta D, Kassir M, et al. Acanthosis nigricans: A review. *J Cosmet Dermatol.* Aug 2020;19(8):1857-1865. doi:10.1111/jocd.13544
6. Stoner RC, Ophaug S, Simpson E, Hanifin J. Acute Pancreatitis in 2 Adolescent Boys on Dupilumab Therapy for Atopic Dermatitis. *Dermatitis.* Jan-Feb 01 2021;32(1):e21-e23. doi:10.1097/der.0000000000000651
7. Kurokawa Y, Oikawa Y, Shimada A, Yajima K. Dupilumab-related type 1 diabetes in a patient with atopic dermatitis: a case report. *Diabetol Int.* Jan 2022;13(1):300-303. doi:10.1007/s13340-021-00526-1