

## BRIEF ARTICLE

## A Rare Case of Pemphigoid Gestationis

Sonia Patel, BA<sup>1</sup>, Lauren Okon, MD<sup>2</sup><sup>1</sup> Cooper Medical School of Rowan University, Camden, New Jersey, USA<sup>2</sup> Macaione and Papa Dermatology, Voorhees, New Jersey, USA

## ABSTRACT

Pemphigoid gestationis (PG) is a condition that arises in pregnant women, typically presenting with pruritic and urticarial plaques and/or bullae involving the umbilicus. This report discusses a 36-year-old woman, 26 weeks pregnant, who presented with an intensely pruritic rash that spread from her thighs to her abdomen, forearms, and toe. Physical examination revealed annular pink papules and plaques, notably lacking bullae and sparing the umbilicus. Biopsy and direct immunofluorescence confirmed PG as well as the presence of serum BP180 antibodies. She responded well to clobetasol and cetirizine, and due to preeclampsia delivered preterm. PG is a rare condition that must be considered in pregnant patients promptly in order to avoid complications for both the mother and child.

## CASE REPORT

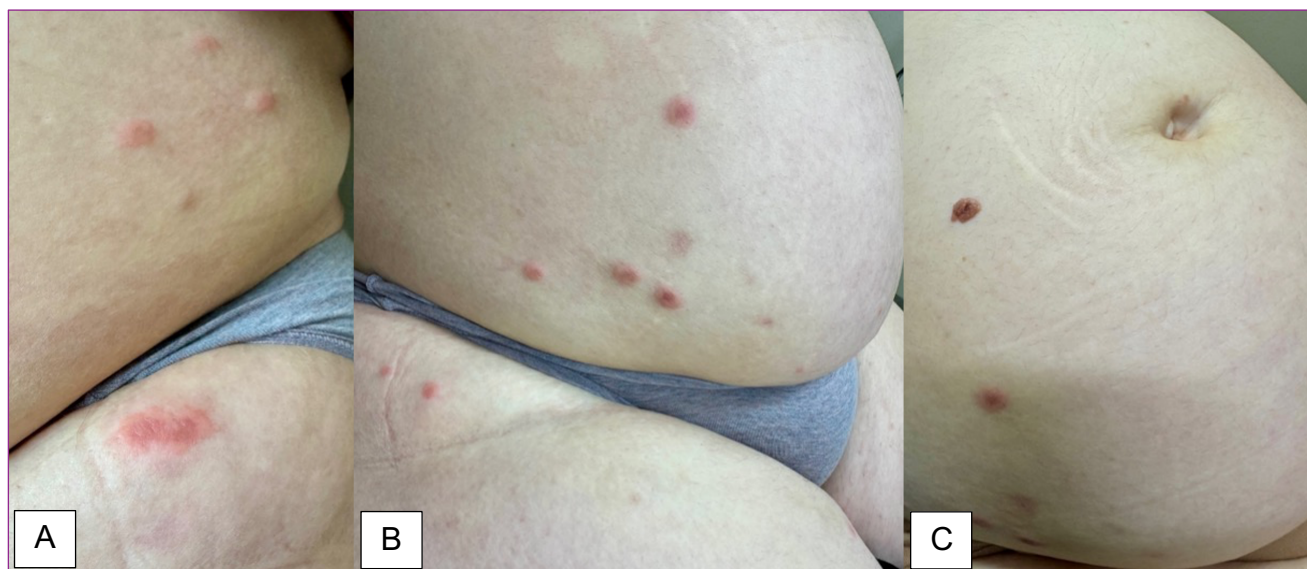
A 36-year-old Turkish-born woman (gravida 2, para 1) presented to the office at 26 weeks' gestation with a two-week history of an extremely pruritic rash. The patient stated that the rash began on her thighs, then spread to the lower abdomen, forearms, and right dorsal toe. One week after the rash appeared, she was diagnosed with Influenza-B Virus Associated Pneumonia in the Emergency Department. She received Tamiflu and cefuroxime at the time of her visit and later recovered with a resolving cough. Her past medical history is significant for asthma, preeclampsia and preterm delivery at 29 weeks of gestation with her previous pregnancy, cold sores, and Herpes Simplex Virus encephalitis 20 years ago. The patient was currently taking 81 mg of acetylsalicylic aspirin, prenatal vitamins, and an albuterol inhaler as needed.

Physical examination findings revealed annular pink papules and plaques, some targetoid in appearance (**Figure 1**). On the right dorsal toe, one vesicular papule was noted. Notably, the rash largely spared the umbilicus. (**Figure 2**).

Differential diagnoses for this patient included insect bites, papular urticaria, erythema multiforme, nodular scabies, and atypical hand foot and mouth disease. Differential diagnoses for pregnancy dermatoses included urticarial pemphigoid gestationis, pruritic urticarial papules and plaques of pregnancy (PUPPP), and atopic eruption of pregnancy. Punch biopsies of the right proximal posterior upper arm and left lateral abdomen were taken.

Punch biopsies revealed spongiosis and parakeratosis in the epidermis (**Figure 3**). In the epidermal-dermal junction, perivascular and interstitial inflammatory infiltrate consisting of lymphocytes, histiocytes, and

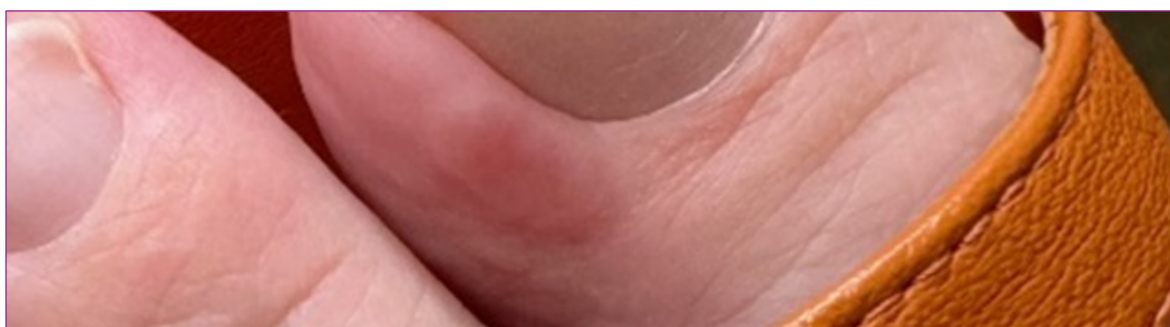
January 2025 Volume 9 Issue 1



**Figure 1.** Pruritic, annular pink papules and plaques in the upper thigh (A) and lower abdomen (B), sparing the umbilicus (C).

eosinophils were seen (**Figure 4**). Direct immunofluorescence of the biopsies was positive for dense linear C3, IgE, and IgG deposits in the basement membrane zone. Furthermore, antibody testing performed on the patient's blood sample revealed the presence of 82 U/mL of bullous pemphigoid 180 (BP180) antibodies. A level of 14 U/mL or less indicates a negative result. BP230 antibodies were negative.

The patient was treated with clobetasol ointment and cetirizine. The patient responded well to these treatments and did not require oral steroids. She delivered her child preterm at 35 weeks via C-section due to pre-eclampsia. The infant was not born with any lesions and the patient noted that her pruritus improved after delivery but that she continued to get scattered spots for 6 weeks postpartum.



**Figure 2.** One slightly vesicular papule noted on the lateral nail fold of the patient's dorsal toe.

## DISCUSSION

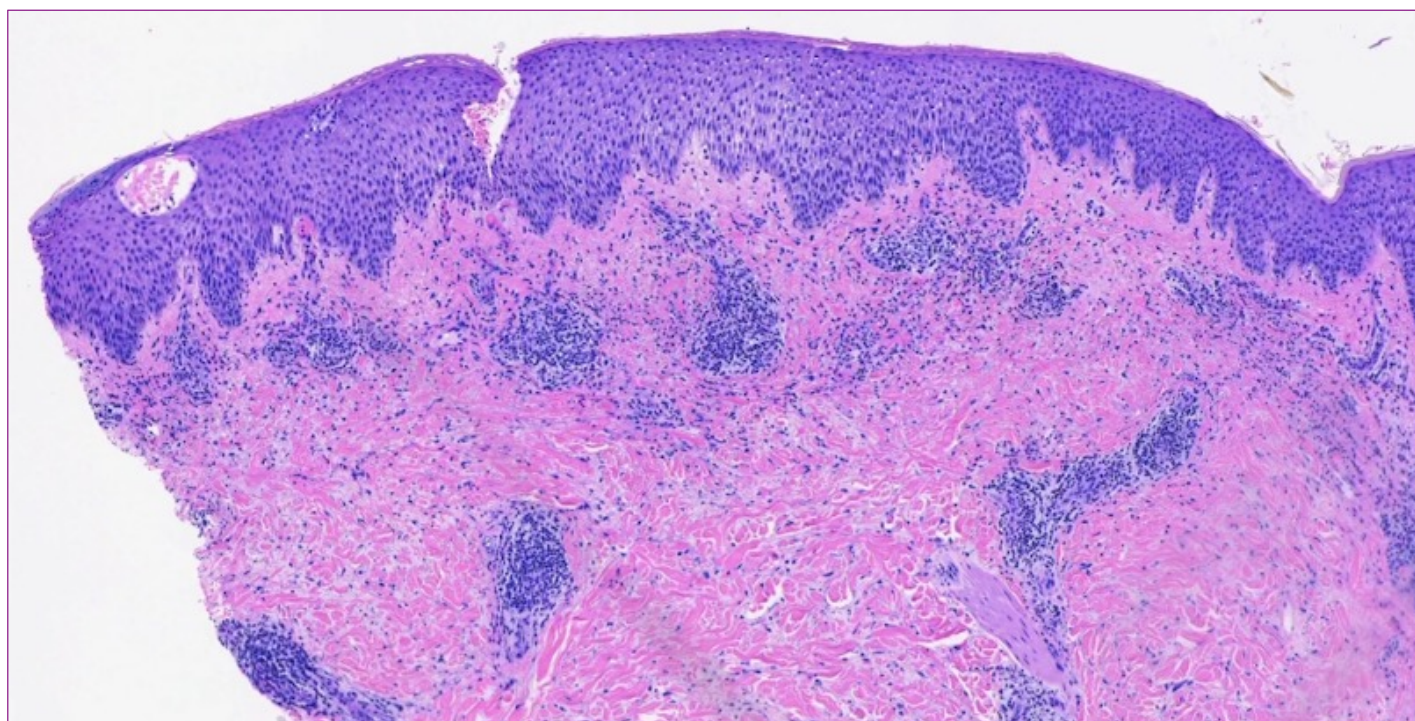
Pemphigoid gestationis (PG), formerly known as herpes gestationis is a rare autoimmune blistering subtype of bullous pemphigoid in

which the body develops auto-antibodies to proteins found in the skin during pregnancy. This condition is most commonly seen during the third trimester; however, it can be seen in either of the other two trimesters, or even during the postpartum period.<sup>1,2</sup> PG may also

develop during the time of delivery or during the reestablishment of the menstrual cycle or with use of contraception.<sup>3</sup> Additionally, one study found that PG may be seen in 33 to 50% of patients in subsequent pregnancies.<sup>2</sup>

PG has an incidence of 1/50,000 individuals and around 10% of infants will develop urticarial lesions from this condition at birth.<sup>4</sup> Neonates born to mothers with this condition may be delivered prematurely or may exhibit an intrauterine limit of growth resulting in smaller size.<sup>1</sup> Patients with increased

frequency of HLA-B8, HLA-DR3, HLA-DR4 have been found to have an increased risk of developing PG during pregnancy.<sup>5-7</sup> Prevalent comorbidities seen in PG patients consist of Graves' disease, Hashimoto's thyroiditis, systemic lupus erythematosus, pernicious anemia, vitiligo, alopecia areata, and ulcerative colitis.<sup>6-9</sup> This disease is also more commonly seen in older, Caucasian women and in subsequent pregnancies.<sup>10</sup> In most patients, their symptoms lessen as their pregnancy progresses.

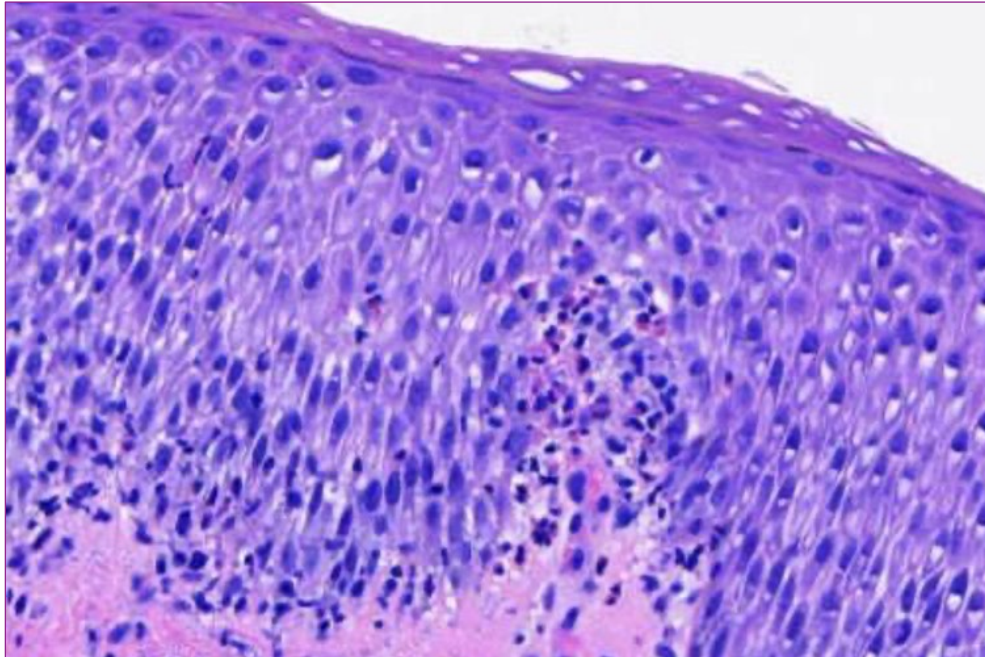


**Figure 3.** Punch biopsy results demonstrating spongiosis and parakeratosis in the epidermis with a perivascular and interstitial inflammatory infiltrate consisting of lymphocytes, histiocytes, and eosinophils (H&E, original magnification x100).

The characteristic symptom of PG is pruritus, followed by urticarial papules and plaques distributed throughout the body which can develop into tense vesicles or bullae. Lesions commonly begin periumbilically and extend into the trunk and extremities including the palmar and plantar surfaces. This condition normally spares the mucous membranes and face.<sup>3</sup>

The exact cause of PG is not known. As an autoimmune condition, the disease begins when the body recognizes its own antigens as foreign. The targeted protein of this condition is one of the basement membrane zone known as BP180, which is a transmembrane hemidesmosome.<sup>11</sup> BP180 is found in the basement membrane of the skin, as well as the cytotrophoblastic and





**Figure 4.** Numerous eosinophils are seen lining the dermal-epidermal junction and within the epidermis (H&E, original magnification x400).

syncytiotrophoblastic cells of the placenta, and the amniotic membrane epithelium.<sup>1</sup> BP230, another membrane protein, is also associated with this condition and is found in the same tissue types. It is thought that the condition develops through loss of immune tolerance which causes the development of abnormal MHC II molecules. The expression of these MHC II molecules results in an auto-attack and inflammation.<sup>12</sup>

The diagnosis of PG consists of examining a biopsy of the epidermal-dermal junction along with direct immunofluorescence (DIF). In skin biopsies, it is common to find cells of inflammatory origin such as eosinophils, lymphocytes, and histiocytes.<sup>3</sup> Vesicles or bullae, seen in some cases, are subepidermal. DIF of PG characteristically shows a linear deposition of C3 at the basement membrane zone. DIF is highly sensitive to this condition and is considered the method used for diagnosis.<sup>13</sup>

In cases of PG with sparing of the umbilicus, particularly in cases in which vesicles or bullae are absent, it may be challenging to make the diagnosis of PG. For patients with existing atopic dermatitis, prurigo gestationis can appear as eczematous plaques on flexor surfaces that include the face.<sup>14</sup> PUPPP is distinguished from PG as this condition typically excludes the periumbilical area and classically begins in abdominal striae.<sup>14</sup>

The treatment of PG is dependent on the severity and staging of the disease, with topical corticosteroids, antihistamines, and oral steroids often employed. In severe refractory cases, steroid-sparing immunosuppressants or intravenous immunoglobulins have been used with success.<sup>1</sup> This condition typically remits postpartum, however, a systematic review by Genovese et al found a 60.6% relapse rate with 25% of patients experiencing a persistent course, and 40% having a recurrence in subsequent pregnancies.<sup>15</sup> Fetal growth restriction and prematurity have

been associated with PG and a reported 13% of newborns born to mothers with PG had urticarial and/or bullous lesions develop.<sup>8,15</sup>

## CONCLUSION

Subtle cases of PG can present with minimal periumbilical involvement and lack of bullae formation, both considered to be classic hallmarks of this disease. Despite an overall favorable maternal and fetal prognosis, it is critical to consider this diagnosis, which can be associated with fetal complications and recurrent lesional outbreaks postpartum. A DIF, antibody testing, as well as discussion with the patient's Obstetrician should be considered in severely pruritic pregnant patients with urticarial plaques who may be presenting with inconspicuous cases of this condition.

**Conflict of Interest Disclosures:** None

**Funding:** None

### Corresponding Author:

Name Sonia Patel  
401 Broadway, Camden, NJ 08103  
Phone: (856) 780-2465  
Email: [patels129@rowan.edu](mailto:patels129@rowan.edu)

### References:

1. Fong M, Gandhi GR, Gharbi A, Hafsi W. Pemphigoid gestationis. *StatPearls* [Internet]. February 12, 2024. Accessed July 8, 2024. <https://www.ncbi.nlm.nih.gov/books/NBK470287/>
2. Sävervall C, Sand FL, Thomsen SF. Pemphigoid gestationis: Current perspectives. *Clin Cosmet Investig Dermatol*. 2017;10:505-513. Accessed July 8, 2024. <https://www.ncbi.nlm.nih.gov/pmc/articles/PM C5685197/>
3. Campbell SM, Balazs K, Conroy M. Pemphigoid gestationis: A case report and review of the literature. *Cutis*. 2011;88(1):21-26.
4. Jiao H-N, Ruan Y-P, Liu Y, Pan M, Zhong H-P. Diagnosis, fetal risk, and treatment of pemphigoid gestationis in pregnancy: A case report. *World J Clin Cases*. 2021;9(34):10535-10541. Accessed July 8, 2024. <https://www.ncbi.nlm.nih.gov/pmc/articles/PM C8686145/>
5. Shornick JK, Stastny P, Gilliam JN. High frequency of histocompatibility antigens HLA-DR3 and DR4 in herpes gestationis. *J Clin Invest*. 1981;68(3):553-555.
6. Shornick JK, Black MM. Secondary autoimmune diseases in herpes gestationis (pemphigoid gestationis). *J Am Acad Dermatol*. 1992;26(4):563-566.
7. Holmes RC, Black MM. Herpes gestationis: A possible association with autoimmune thyrotoxicosis (Graves' disease). *J Am Acad Dermatol*. 1980;3(5):474-477.
8. Ambros-Rudolph CM. Dermatoses of pregnancy - clues to diagnosis, fetal risk and therapy. *Ann Dermatol*. 2011;23(3):265-275. Accessed July 8, 2024. <https://synapse.koreamed.org/articles/1045334>
9. Abdelhafez M, Than W, Helmy E, et al. Pemphigoid gestationis and adverse pregnancy outcomes: A literature review. *J Gynecol Obstet Hum Reprod*. 2002;51(5):102370.
10. Pemphigoid gestationis. American Osteopathic College of Dermatology (AOCD). Accessed July 8, 2024. <https://www.aocd.org/page/PemphigoidGestation>
11. Tuusa J, Kokkonen N, Tasanen K. BP180/Collagen XVII: A molecular view. *Int J Mol Sci*. 2021;22(22):12278. Accessed July 8, 2024. <https://www.ncbi.nlm.nih.gov/pmc/articles/PM C8623354/>
12. Semkova K, Black M. Pemphigoid gestationis: Current insights into pathogenesis and treatment. *Eur J Obstet Gynecol Reprod Biol*. 2009;145(2):138-144. doi:10.1016/j.ejogrb.2009.05.012
13. Hallaji Z, Mortazavi H, Ashtari S, Nikoo A, Abdollahi M, Nasimi M. Pemphigoid gestationis: Clinical and histologic features of twenty-three patients. *Int J Women's Dermatol*. 2016;2(4):140-145. Accessed July 8, 2024. <https://www.ncbi.nlm.nih.gov/pmc/articles/PM C5440447/>
14. Studdiford JS, George N, Traves K. Pruritic rash in pregnancy. *Am Fam Physician*. 2017;95(7):453-460. Accessed July 8, 2024.

January 2025 Volume 9 Issue 1

<https://www.aafp.org/pubs/afp/issues/2017/0401/p453.html>

15. Genovese G, Muratori S, Berti E, et al. A systematic review of treatment options and clinical outcomes in pemphigoid gestationis. *Front Med (Lausanne)*. 2020;7:604945. doi:10.3389/fmed.2020.604945